



# Use of Dermasilk briefs in recurrent vulvovaginal candidosis: safety and effectiveness

A. D'Antuono,<sup>1</sup> E. Baldi,<sup>2</sup> S. Bellavista,<sup>1</sup> N. Banzola,<sup>1</sup> S. Zauli<sup>1</sup> and A. Patrizi<sup>1</sup>

<sup>1</sup>Section of Dermatology, Department of Internal Medicine, Geriatrics and Nephrology, University of Bologna, Bologna, Italy and <sup>2</sup>Department of Medicine and Public Health, University of Bologna, Bologna, Italy

## Summary

Despite the generally excellent results achieved with fluconazole 150 mg weekly in recurrent vulvovaginal candidosis (RVVC), some patients with a long history of disease do not achieve complete resolution of symptoms following antimycotic treatment. It is thought that use of tight synthetic fabric underwear could be a significant factor in causing recurrence. We decided to compare underwear made of Dermasilk<sup>®</sup>, a pure fibroin fabric impregnated with a permanent antimicrobial protection, with a cotton placebo to see whether it could be a useful adjunctive tool in the management of RVVC. We recruited 96 women who had a long-term history of RVVC and had not responded to oral antimycotics with complete satisfaction. The patients were randomly divided into two groups and instructed to use either white cotton placebo briefs or Dermasilk<sup>®</sup> briefs. Both groups were treated with fluconazole 150 mg once weekly for 6 months. After 6 months, the Dermasilk group showed a statistically significant greater decrease of itching, burning, erythema and a smaller number of recurrences than the cotton group. Our work suggests that Dermasilk<sup>®</sup> briefs could be a useful adjunctive tool in addition to antimycotic treatment to help relieve the discomfort of recurrent vulvovaginitis.

**Key words:** Recurrent vulvovaginal candidosis, Dermasilk, antimicrobial textile.

## Introduction

Recurrent vulvovaginal candidosis (RVVC), defined as four or more episodes of *Candida* vaginitis in 1 year, affects about 5–8% of adult women.<sup>1</sup> According to the literature, the most effective treatment of RVVC is oral fluconazole 150 mg weekly for at least 6 months during which no recurrences occur in about 90% of cases.<sup>2</sup> Despite the excellent results achieved with fluconazole, it has been our experience that there is a small, but clinically significant cohort of patients with a long history of RVVC who, despite antimycotic treatment, suffer from persistent symptomatology and may require additional treatments.<sup>3</sup>

The pathogenesis of vulvovaginal candidosis (VVC) is complex and influenced by many factors.<sup>1</sup> One of the proposed predisposing factors is the popular use of tight synthetic fabric briefs that may help create a favourable environment for *Candida* germination by increasing dampness around the vulvar area.<sup>4,5</sup> We therefore decided to investigate the comparative influence of two different types of briefs in the long-term management of RVVC. We compared the effect of standard cotton placebo underwear with underwear made of Dermasilk<sup>®</sup> (Alpretec Srl, San Donà di Piave, Venice, Italy) in a group of women suffering from RVVC during treatment with an oral antimycotic. Dermasilk<sup>®</sup> is a pure silk fibroin fabric impregnated with a permanent antimicrobial protection agent (AEM 5772/5) that has been shown to be useful as an adjunct in the treatment of atopic dermatitis<sup>6–8</sup> and vulval lichen sclerosis.

## Subjects and methods

In this 6 months study, we recruited women older than 18 years, attending a Centre for Sexually Transmitted

Correspondence: S. Bellavista, Division of Dermatology, University of Bologna, Via Massarenti 1, 40139 Bologna, Italy.  
Tel.: +39 051 6363319. Fax: +39 051 347847.  
E-mail: sara.bellavista4@unibo.it

Accepted for publication 4 August 2011

Diseases with a history of long-term RVVC (from 1 to 6 years, mean time 2.4 years). All patients had a past history of treatment with weekly oral fluconazole for a period of at least 6 months during which they had continued to experience vulvar irritation that failed to resolve. In addition, many of these patients had also been treated with topical antimycotics, *Lactobacillus* vaginal tablets, topical boric acid and homeopathy without success. Patients affected by the following conditions were not eligible to participate in the study: pregnancy, diabetes mellitus, HIV seropositivity, vulvar dermatological diseases, lichen sclerosus, current use of oral contraceptives and oral antibiotics and oral or topical antimycotic agents during the previous 4 weeks.

At the time of recruitment, eligible patients presented with an episode of acute VVC, a positive culture from vaginal discharge for *Candida* and a vaginitis severity score  $\geq 3$  as described by Sobel *et al.* [9]. This severity scoring system evaluates symptoms (itching, irritation and burning) and signs (erythema, oedema and excoriations or fissures). The severity of each sign and symptom was scored on a scale of 0 (absent) to 3 (severe). In each patient, bacterial vaginosis was excluded by pH measurement and Gram stain microscopy. The isolation of *Candida* and the identification of the species were obtained by cultures on chromogenic agar (CHROMagar *Candida*, Vacutest Kima, Padova, Italy)<sup>10</sup>; when CHROMagar did not allow certain identification of the species, an automated yeast biochemical identification system was used (Vitek card, BioMérieux, Marcy-l'Etoile, France).<sup>11</sup>

Women who entered the study were treated with fluconazole 150 mg weekly for 6 months. In addition, a sealed anonymous envelope containing either three pairs of white Dermasilk briefs or three pairs of white cotton briefs, was given to each patient. The study was double-blinded and each envelope containing briefs was identified by a progressive number; correspondence between the envelope number and its content was revealed by the producer of briefs only at the end of the study. Patients were asked to wear only these briefs, day and night for the 6 months duration of the study. During the follow-up visits, after 1, 3 and 6 months, cultural examination for *Candida* and scoring of symptoms and signs were repeated. A severity score  $\geq 3$  with positive culture was considered a recurrence. Considering every single symptom and sign, a lower score at follow-up visit was evaluated as an improvement, a higher score as a worsening.

Statistical analysis was performed with SPSS 17 and Stata 10 for Windows. Data were expressed as ordinal variables, and so they were summarised as prevalence

and frequency; Fisher exact test and Pearson chi square were used to highlight differences between the groups.

## Results

One hundred patients with recurrent VVC were recruited, but four were lost during follow-up, and so 96 women completed the study. Ages ranged from 18 to 52 years (median age 30.25). Yeast cultures revealed *Candida albicans* in 82 patients, *Candida glabrata* in 11 and *Candida parapsilosis* in three patients. The patients were randomly divided into two groups: Dermasilk<sup>®</sup> briefs were given to 48 patients (DS group), whereas cotton briefs were given to the other 48 women (CT group).

No statistically significant difference was found between the age of the two groups: median age of the DS group was 32 years (IQR: 25–39.5 years), whereas that of the CT group was 28.5 years (IQR: 25–37.5 years). Mean duration of recurrent VVC and incidence of symptoms and signs did not statistically differ between the two groups, even though burning and dyspareunia were slightly more frequent in the DS group. No patients reported side effects in either arm of the study.

Both arms of the study showed similar reductions of symptoms and signs within the first month of the study, but after 3 months there appeared to be a divergence developing in favour of the DS group with regard to itching, burning and erythema.

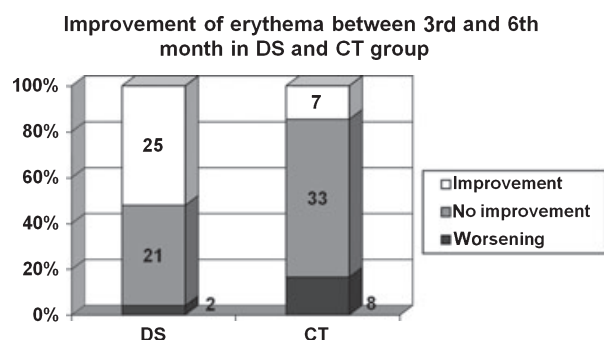
At the 6-month time point, the patients in the DS group showed a significantly greater decrease of itching and erythema (Fisher exact test  $P < 0.0001$ ) and burning (Fisher exact test  $P < 0.05$ ) than the CT patients as shown in Table 1.

Severity scores of symptoms and signs recorded during the follow-up visits showed an improvement after 1 month, whereas after 3 and 6 months, some symptoms and signs worsened, more frequently in CT group (data not shown). A statistically significant different trend between the two groups was gained at the end of the study for erythema with 25/48 (52.08%) patients in DS group, but only 7/48 (14.58%) in CT group showing an improvement in erythema between the 3rd and the 6th month (Pearson Chi square = 16.392;  $P < 0.0001$ ) (Fig. 1).

Eleven of the 48 (22.91%) patients in the DS group did not report any recurrences during the study compared with only four of the 48 (8.3%) patients of the CT group. (Fisher exact test  $P = 0.036$ ). Most patients in the DS group (32/48, 66.7%) had no or one recurrence, whereas in the CT group, most (29/48,

**Table 1** Prevalence (in number) of vulvovaginal symptoms and signs in DS (patients wearing Dermasilk® briefs) and CT (patients wearing white cotton briefs) groups at the different checks; severity scores were not considered in this table, all symptoms and signs being considered only as present or absent (Fisher exact test \* $P < 0.05$ ; \*\* $P < 0.01$ , \*\*\* $P < 0.0001$ ).

	Baseline		After 1 month		After 3 months		After 6 months	
	DS	CT	DS	CT	DS	CT	DS	CT
Symptoms								
Itching	48	48	39	42	20	30	6***	28
Burning	38	29	19	19	5	8	1*	8
Skin irritation	42**	28	11	13	3	6	0 $P = 0.056$	5
Clinical signs								
Erythema	48	48	43	44	29	35	6***	38
Oedema	43	39	17	19	1	3	1	3
Excoriations/fissures	23	11	6	6	1	0	0	0



**Figure 1** Improvement of erythema at 6 months in DS (patients wearing Dermasilk® briefs) and CT (patients wearing white cotton briefs) groups, calculated on the difference of severity scores between 3rd and 6th month. During the last 3 months of the study, erythema continues to improve in DS group, whereas it remains stable or worsens in CT group.

60.5%) had two or more recurrences (Table 2). Results of mycological cultures are summarised in Table 3. Culture was positive for *C. glabrata* in four women of DS group and seven of CT group; *C. parapsilosis* was found in two women of DS group and one of CT group. In both groups, patients positive for these species were more prone to recurrences.

## Discussion

Despite its benign nature, RVVC represents a frequent cause for medical consultation and a significant reduc-

**Table 2** Number of patients of DS (patients wearing Dermasilk® briefs) and CT (patients wearing white cotton briefs) groups that developed no, one, two or three recurrences during the whole study (Fisher exact test  $P = 0.036^*$ ).

Recurrences	DS (48 patients)	CT (48 patients)	All patients (96p)
No recurrences	11*	4	15
One recurrence	21	15	36
Two recurrences	14	20	34
Three recurrences	2	9	11

**Table 3** Positive results of mycological cultures at baseline, after 1, 3 and 6 months.

	At baseline	After 1 month	After 3 months	After 6 months
<i>Candida albicans</i> (n)	82	47	33	21
<i>Candida glabrata</i> (n)	11	9	10	11
<i>Candida parapsilosis</i> (n)	3	1	3	2
Positive cultures (n)	96	57	46	34

tion in quality of life of the affected women. Usually treatment with fluconazole 150 mg weekly for 6 months is well tolerated and efficacious, but often VVC recurs once therapy is stopped and clear guidelines about the length of treatment are not available. In addition, some patients do not obtain a complete therapeutic and symptomatic resolution during treatment. Several explanations of this phenomenon have been hypothesised. *Candida albicans* seems to develop diminished fluconazole sensitivity after prolonged exposure.<sup>12,13</sup> Also, other *Candida* species are frequently resistant to fluconazole.<sup>14,15</sup> The receptivity to yeast of vaginal epithelial cells may be increased by expression of polymorphism of mannose-binding lectine gene, thus making some patients more prone to develop candidosis.<sup>16</sup> Finally, some patients with recurrent VVC seem to develop a vaginal allergic immune response against *Candida*, with the production of *Candida*-specific IgE that impairs T cell immune response and cytokine secretion. This acquired immune defect may alter the integrity of the mucosa and its barrier function, and consequently prolong chronic vaginal symptoms.<sup>17</sup>

Although antimycotic therapy is the treatment of first choice, patients with these complicating features may require additional therapeutic measures including advice on appropriate underwear. In the past, doctors have instinctively tended to advise patients to wear cotton underwear because cotton is a natural soft fabric, but there is no clinical evidence to support this practice. Dermasilk® is a high technology fine-knitted natural

fabric made of 100% pure fibroin (medical grade sericin-free silk) impregnated with a non-migrating permanent antimicrobial protection (AEM 5772/5). Its physical properties suggest it could be an ideal fabric for use in RVVC. The removal of sericin minimises the possibility of any contact allergic reaction, and it has extremely low frictional properties due to its long, smooth cylindrical filaments. The protein structure of fibroin is similar to the stratum corneum of the human skin, so that Dermasilk<sup>®</sup> is able to absorb a high percentage of moisture without becoming damp, maintaining a stable heat and humidity balance next to the skin and constant skin temperature.

The antimicrobial AEM 5772/5 (3-trihydroxysilyl propyldimethyloctadecyl ammonium chloride) is a quaternary ammonium compound that is bonded permanently to the fabric and cannot be washed or worn off. This compound kills microorganisms that come into contact with it by puncturing the cell wall and inducing a mechanical cellular lysis. It is not released from the fabric and so does not migrate onto the skin to alter local resident flora, unlike other antimicrobial finishes. AEM5772/5 has been extensively used in hospitals for over three decades and in DermaSilk for nearly 10 years, and has been shown not to irritate human tissues.

Dermasilk<sup>®</sup> has been demonstrated to be significantly more effective than cotton in the management of atopic dermatitis.<sup>6–8</sup> *In vitro* studies of this textile have demonstrated a significant decrease in *Staphylococcus aureus*, *Pseudomonas aeruginosa* and *C. albicans*.<sup>18</sup> A study conducted in atopic eczema patients over 28 days demonstrated the benefits of Dermasilk vs. identical silk minus the antimicrobial finish.<sup>19</sup> These features have led to the inclusion of Dermasilk fabric into European guidelines for the management of atopic dermatitis.<sup>20</sup>

The aim of our study was to investigate if Dermasilk<sup>®</sup> underwear may be a useful adjuvant tool in the management of RVVC that had not been completely resolved by antimycotic treatment. In our study, we followed up 96 women affected by recurrent VVC for 6 months; 48 patients used cotton briefs and 48 Dermasilk<sup>®</sup> briefs, in addition to a systemic treatment with fluconazole 150 mg weekly. Strict adherence to wearing briefs assigned during the study was reported in all patients, as they were long-term suffering from VVC and so highly motivated to seek a solution to their problem. All patients showed an improvement after the first month of treatment compared with the previous 4 weeks of wash out. However, signs and symptoms tended to worsen subsequently, also during fluconazole therapy, with a higher statistical frequency in the group

using cotton briefs compared with the Dermasilk group. In fact, at the last follow-up visit, after 6 months, patients using Dermasilk<sup>®</sup> briefs maintained better results compared with women using cotton briefs, with regard to itching, burning and erythema.

The use of Dermasilk<sup>®</sup> briefs seemed to reduce the number of recurrences during antimycotic treatment compared with cotton briefs. The incidence of recurrences in our study is higher than in other reports<sup>21</sup>, but it must be noted that our patients suffered from a particularly persistent form of RVVC and had experienced a high number of VVC episodes during the previous year that had been already treated with long-term antimycotic treatment. Moreover, 11 of our patients had mycological examination positive for *C. glabrata* and three for *C. parapsilosis*; in the literature, these species are often reported to be resistant to a low dose of fluconazole, as also evidenced by the results of our study.

We believe that Dermasilk<sup>®</sup> briefs are helpful in recurrent VVC as a result of the fundamental properties of the fabric. First, the silk fibroin fabric is significantly better than cotton at removing excess moisture and maintaining stable water balance and temperature control, thereby denying the yeast a damp environment for proliferation. Secondly, the AEM 5772/5 antimicrobial finish has demonstrated *in vitro* the ability to decrease *Candida* contamination of the fabric. It does not migrate from the fabric to the skin, and so it does not alter local microbiota such as *Lactobacillus* spp. Finally, Dermasilk<sup>®</sup> decreases external sources of vulvar irritation, thanks to its smooth fibres, and does not exacerbate the immuno-mediated inflammatory processes already present in many women with recurrent VVC, in line with the theory of vaginal allergic immune response against *Candida*.

We appreciate that our study has limitations. The sample consists of women affected by long-term RVVC with a high number of active episodes every year and an incomplete remission after antimycotic treatment. This fact makes it difficult to undertake a comparison with other data in the literature. We are unable to specifically separate the improvement due to the use of fluconazole from that due to the use of specific underwear, but as both sets of patients followed the same fluconazole regime, it is logical to link any variation in outcome with the choice of briefs.

In conclusion, we believe that advice on appropriate underwear could benefit patients suffering from RVVC. This study shows that Dermasilk<sup>®</sup> briefs are safe and comfortable underwear for women suffering from RVVC and appear to provide greater benefit than cotton. They

can contribute to the control of vulvovaginal symptoms by diminishing external sources of irritation, managing local humidity and helping restore skin barrier function. Our data suggest that Dermasilk® briefs could be a useful and safe adjunctive to antimycotic treatment, free of side effects, in patients with persistent and recurrent vulvovaginitis.

## Acknowledgments

Alpretec, producer of Dermasilk briefs, provided materials required to perform the study.

## References

- 1 Sobel JD. Vulvovaginal candidosis. *Lancet* 2007; **369**: 1961–71.
- 2 Watson C, Calabretto H. Comprehensive review of conventional and non-conventional methods of management of recurrent vulvovaginal candidiasis. *Aust N Z J Obstet Gynaecol* 2007; **47**: 262–72.
- 3 Hoffstetter SE, Barr S, LeFevre C, Leong FC, Leet T. Self-reported yeast symptoms compared with clinical wet mount analysis and vaginal yeast culture in a specialty clinic setting. *J Reprod Med* 2008; **53**: 402–6.
- 4 Elegbe IA, Elegbe I. Quantitative relationships of *Candida albicans* infections and dressing patterns in Nigerian women. *Am J Public Health* 1983; **73**: 450–2.
- 5 Corsello S, Spinillo A, Osnengo G *et al.* An epidemiological survey of vulvovaginal candidiasis in Italy. *Eur J Obstet Gynecol Reprod Biol* 2003; **110**: 66–72.
- 6 Senti G, Steinmann LS, Fischer B *et al.* Antimicrobial silk clothing in the treatment of atopic dermatitis proves comparable to topical corticosteroid treatment. *Dermatology* 2006; **213**: 228–33.
- 7 Ricci G, Patrizi A, Bendandi B, Menna G, Varotti E, Masi M. Clinical effectiveness of a silk fabric in the treatment of atopic dermatitis. *Br J Dermatol* 2004; **150**: 127–31.
- 8 Ricci G, Patrizi A, Mandrioli P *et al.* Evaluation of the antibacterial activity of a special silk textile in the treatment of atopic dermatitis. *Dermatology* 2006; **213**: 224–7.
- 9 Sobel JD, Wiesenfeld HC, Martens M *et al.* Maintenance fluconazole therapy for recurrent vulvovaginal candidiasis. *N Engl J Med* 2004; **351**: 876–83.
- 10 Jabra-Rizk MA, Brenner TM, Romagnoli M *et al.* Evaluation of a reformulated CHROMagar Candida. *J Clin Microbiol* 2001; **39**: 2015–6.
- 11 Graf B, Adam T, Zill E, Göbel UB. Evaluation of the Vitek 2 system for rapid identification of yeast and yeast-like organism. *J Clin Microbiol* 2000; **38**: 1782–5.
- 12 Shahid Z, Sobel JD. Reduced fluconazole susceptibility of *Candida albicans* isolates in women with recurrent vulvovaginal candidiasis: effects of long-term fluconazole therapy. *Diagn Microbiol Infect Dis* 2009; **64**: 354–6.
- 13 Bulik CC, Sobel JD, Nailon MD. Susceptibility profile of vaginal isolates of *Candida albicans* prior to and following fluconazole introduction - impact of two decades. *Mycoses* 2011; **54**: 34–8.
- 14 Buitrón García-Figueroa R, Araiza-Santibáñez J, Basurto-Kuba E, Bonifaz-Trujillo A. *Candida glabrata*: an emergent opportunist in vulvovaginitis. *Cir Cir* 2009; **77**: 423–7.
- 15 Arechavala AI, Bianchi MH, Robles AM, Santiso G, Negrón R. Identification and susceptibility against fluconazole and albaconazole of 100 yeast strains isolated from vaginal discharge. *Rev Iberoam Micol* 2007; **24**: 305–8.
- 16 Donders GGG, Babula O, Bellen G, Linhares IM, Witkin SS. Mannose-binding lectin gene polymorphism and resistance to therapy in women with recurrent vulvovaginal candidiasis. *BJOG* 2008; **115**: 1225–31.
- 17 Weissanbacher TM, Witkin SS, Gengelmaier A, Scholz C, Friese K, Mylonas I. Relationship between recurrent vulvovaginal candidosis and immune mediators in vaginal fluid. *Eur J Obstetr Gynecol* 2009; **144**: 59–63.
- 18 Haug S, Roll A, Schmid-Grendelmeier P *et al.* Coated textiles in the treatment of atopic dermatitis. *Curr Probl Dermatol* 2006; **33**: 144–51.
- 19 Stinco G, Piccirillo F, Valent F. A randomised double-blind study to investigate the clinical efficacy of adding a non-migrating antimicrobial to a special silk fabric in the treatment of atopic dermatitis. *Dematology* 2008; **217**: 191–5.
- 20 Darsow U, Wollenberg A, Simon D *et al.* ETFAD/EADV eczema task force 2009 position paper on diagnosis and treatment of atopic dermatitis. *J Eur Acad Dermatol Venereol* 2010; **24**: 317–28.
- 21 Donders G, Bellen G, Bytterbier G *et al.* Individualised decreasing-dose maintenance fluconazole regimen for recurrent vulvovaginal candidiasis (ReCiDiF trial). *Am J Obstet Gynecol* 2008; **199**: 613.