



# Antimicrobial silk clothing as an adjuvant tool in the treatment of chemotherapy-induced skin reactions

Fabbrocini G., Panariello L., Caro G., Bianca D., Romano MC.



### Introduction & Objectives:

Antimicrobial silk clothing is a high technology fine-knitted natural fabric made of 100% silk fibroin bonded with a non-migrating permanent antimicrobial protection (AEM 5772/5).

The removal of sericin minimizes the possibility of any contact allergic reaction; moreover this kind of fabric has extremely low frictional properties due to its long, smooth cylindrical filaments. The protein structure of fibroin is similar to stratum corneum of the human skin, so that fabric is able to absorb a high percentage of moisture without becoming damp, maintaining a stable heat and humidity balance next to the skin and constant skin temperature.

The antimicrobial AEM 5772/5 is a quaternary ammonium compound that is bonded permanently to the fabric and cannot be washed or worn off. **The aim of this study is to analyze antimicrobial silk clothing as an adjuvant tool for the management of chemotherapy induced skin reactions.**

### Materials & Methods:

43 patients referring to our outpatient department dedicated to chemotherapy skin reactions were included. They were affected by hand-foot syndrome (13 patients), papulo-pustular rash (15 patients), radiation dermatitis (10 patients) and paronychia (5 patients).

Informed consent was obtained from all patients.

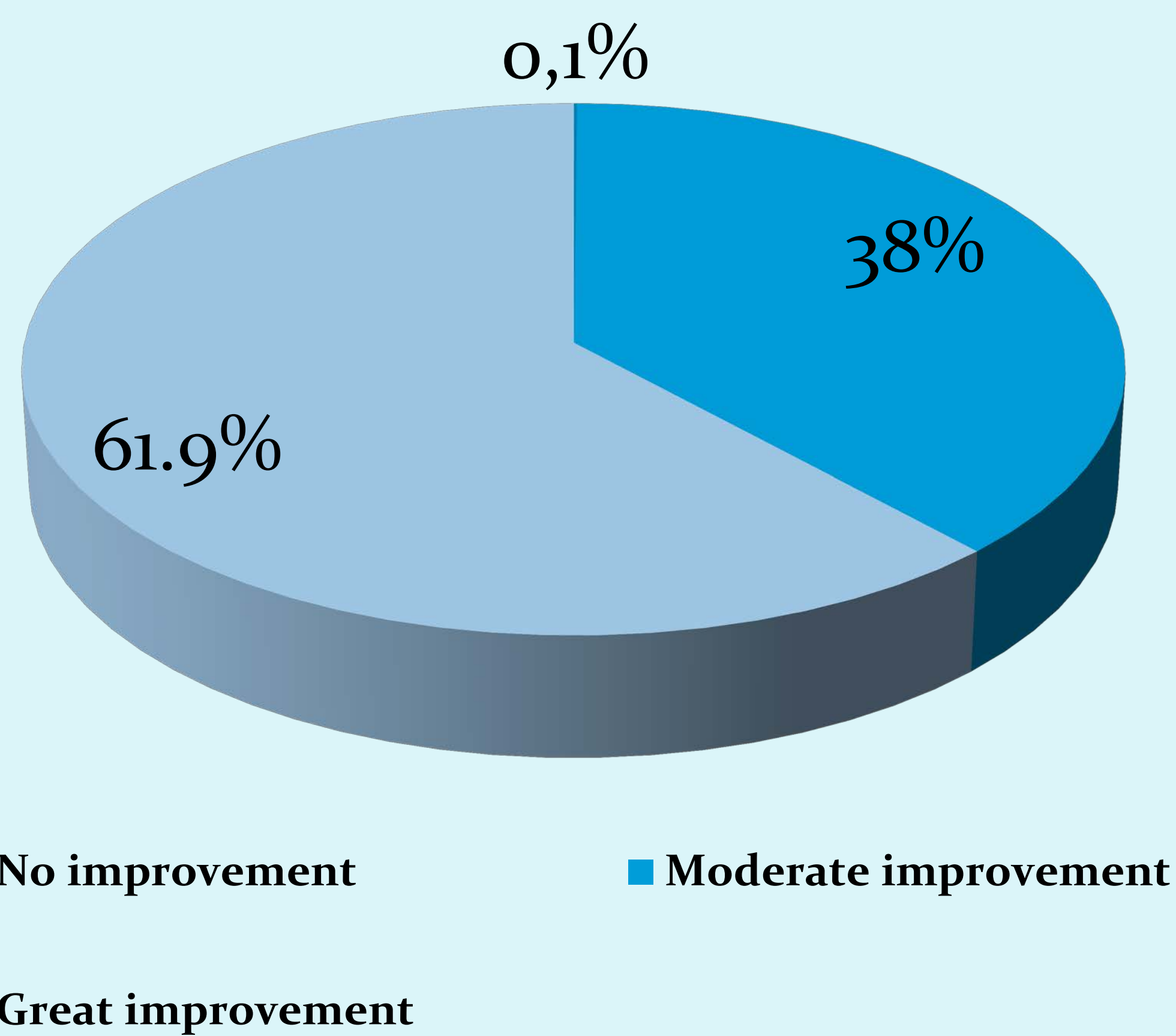
Patients affected by *papulo-pustular rash* were treated with topical antibiotics with antinflammatory action; emollients and keratolytics were used for *hand-foot syndrome*; moisturizer and topical cortico-antibiotics were used for *radiation dermatitis*; *periungual granulomas* were treated with phenol cauterization and acetic acid foot bath.

All patients wore silk clothing in addition to the above-mentioned therapy during the whole time of observation.

Evaluations have been performed by 2 qualified evaluators at T0, after 2 weeks (T1) and after one month (T2). It consisted of:

- Clinical photos
- Subjective symptoms, such as itching, pain, and dysesthesia, through a specific questionnaire
- TEWL, through Tewameter (n.v. 12.73 +/- 3.94 gr/m<sup>2</sup> ). (Patients with paronychia were not included in this kind of evaluation).

Wearing antimicrobial silk clothing



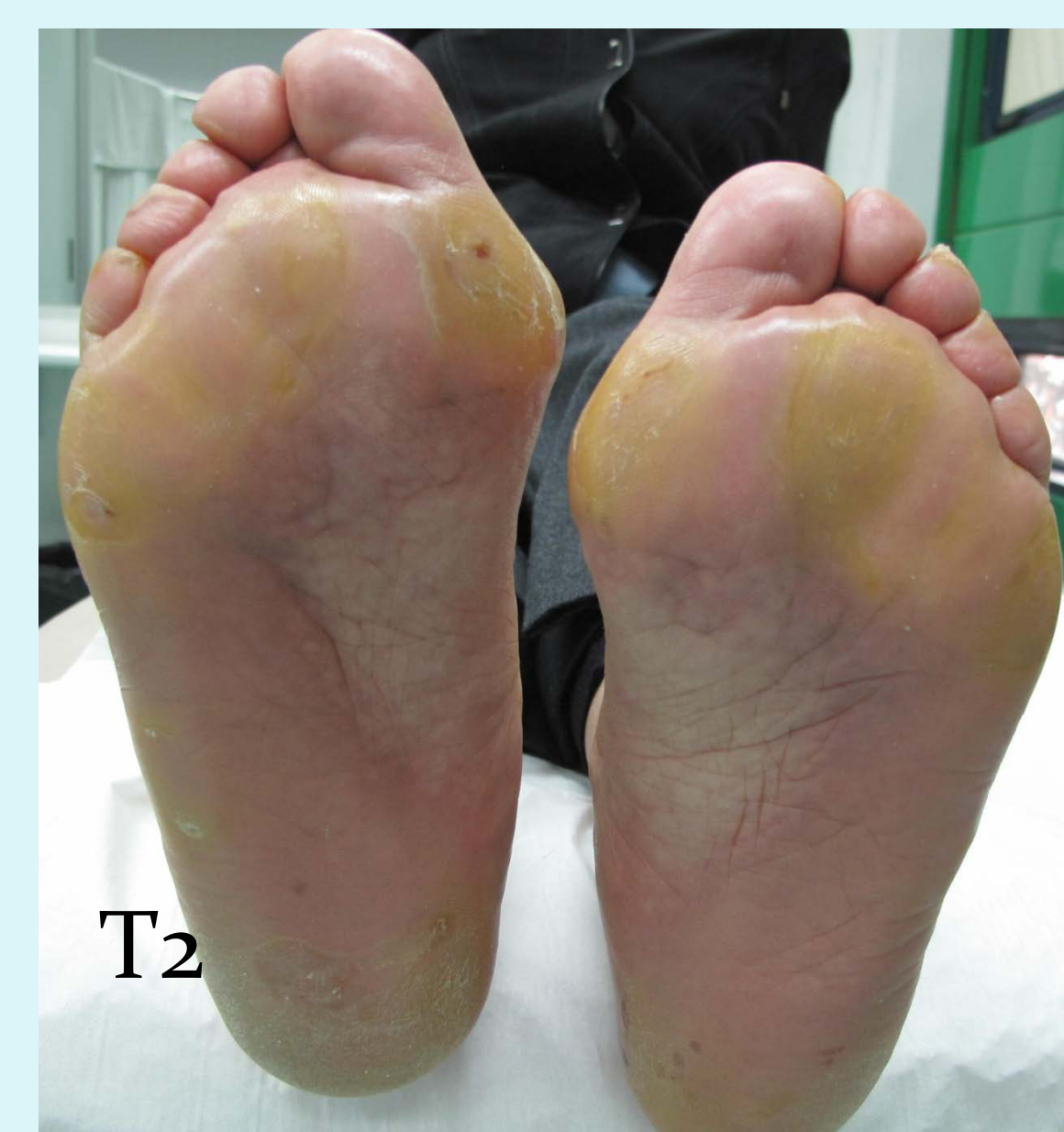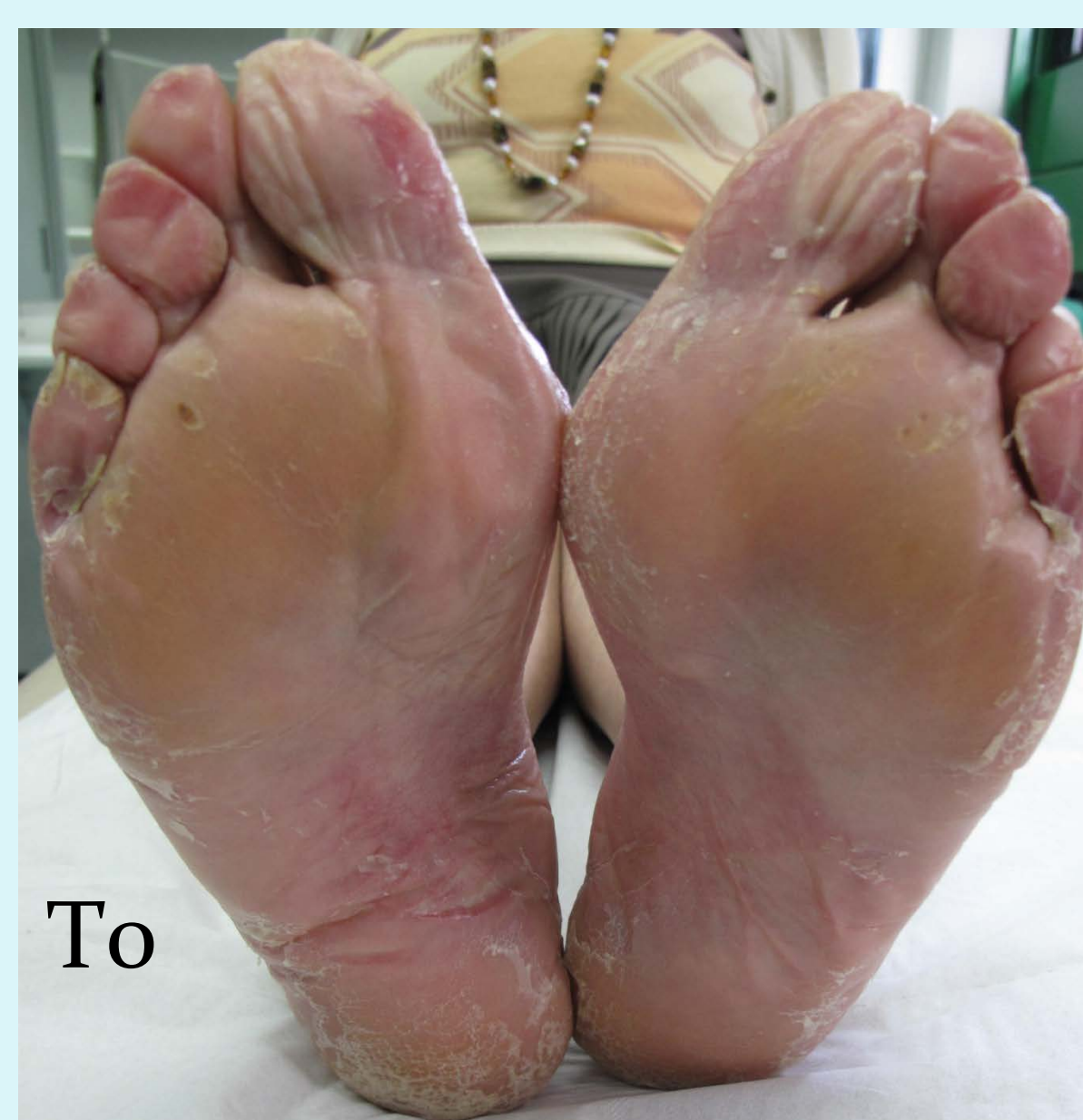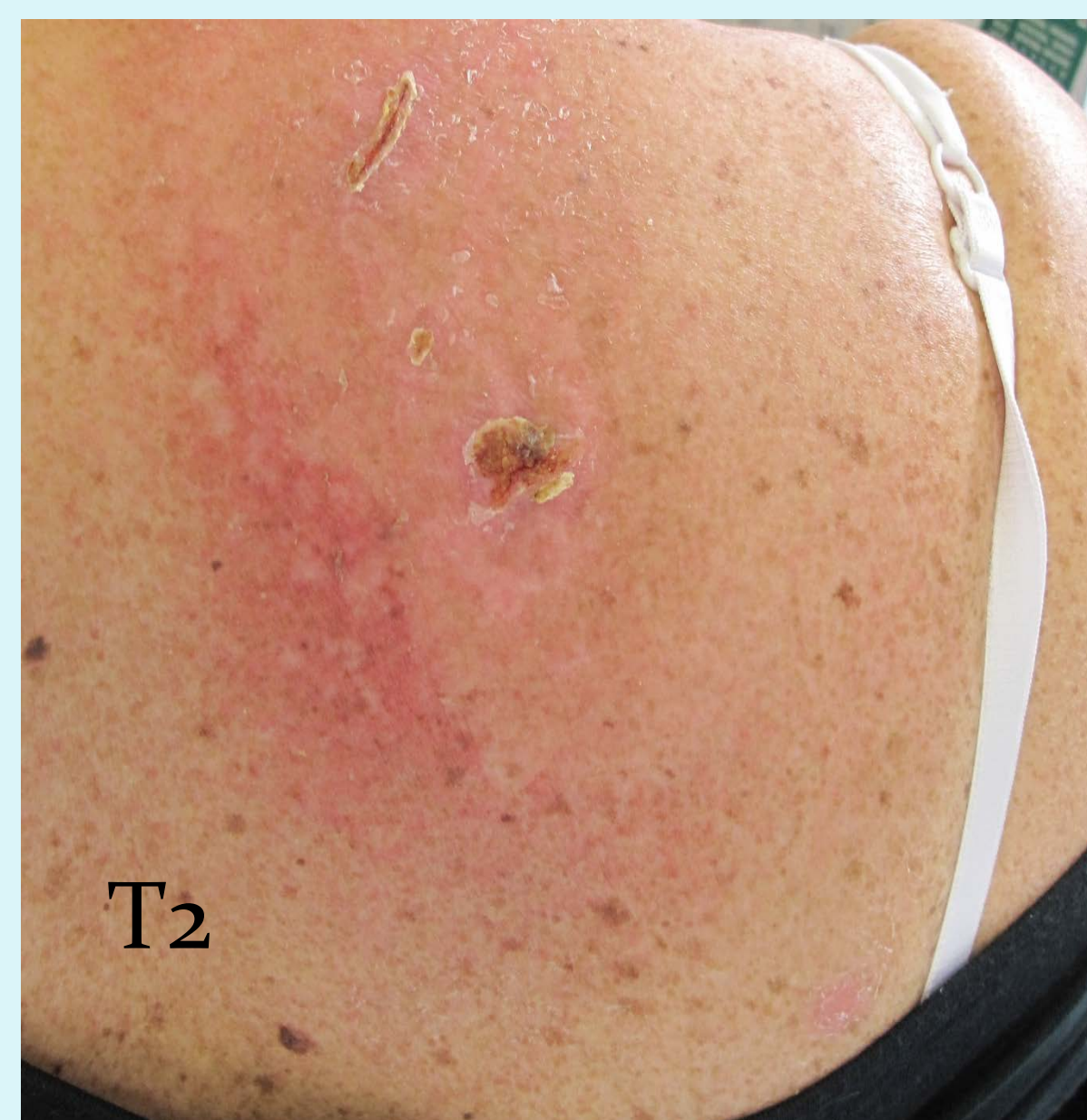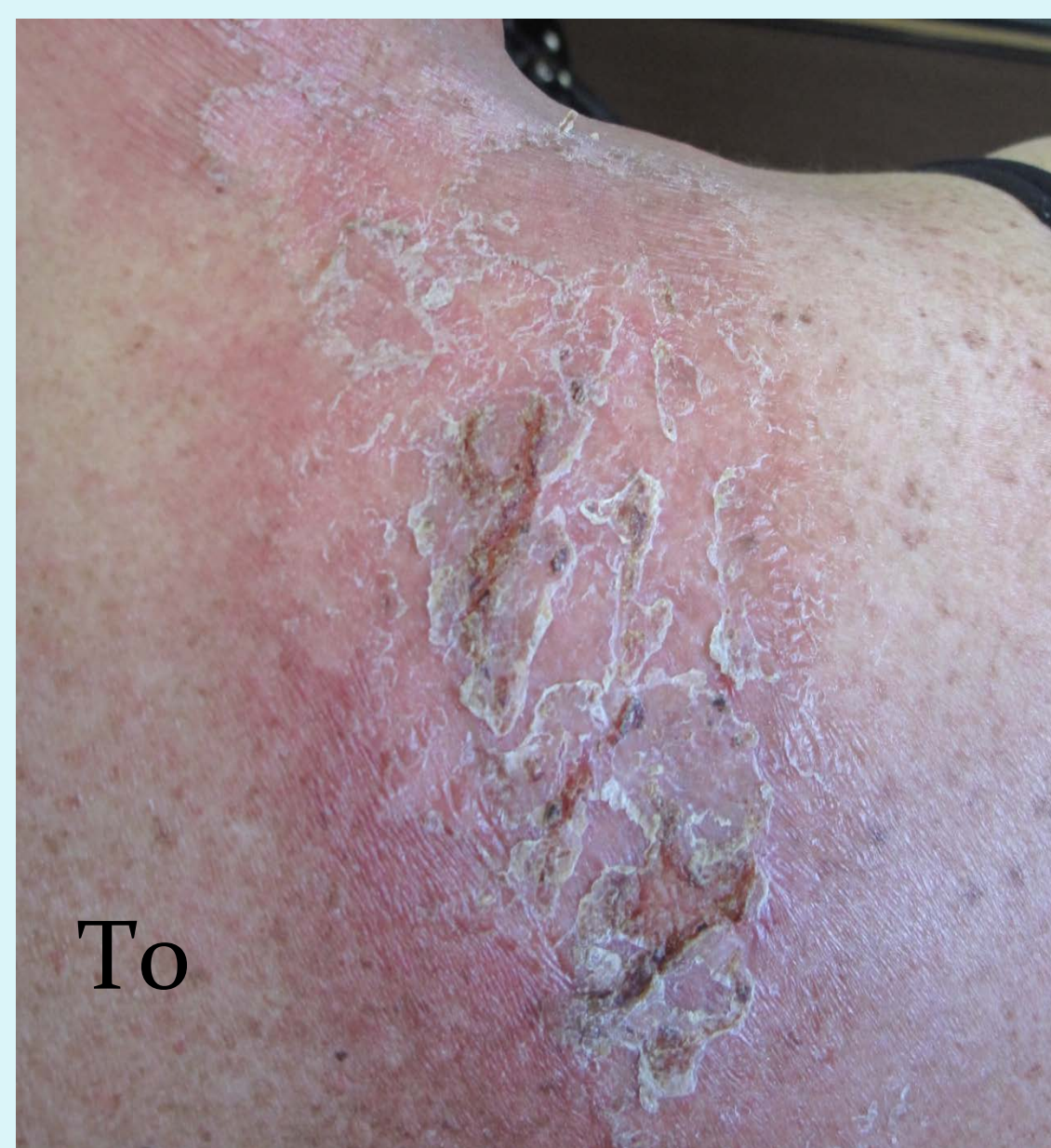### Results:

**Questionnaire:** 61.9% of patients referred great improvement of symptoms and 38.0% referred moderate improvement.

**Tewameter:** T0 medium values was of 19.3 (moderate skin dehydration); T2 medium values was of 13.9 (good skin hydration).

We also notice that the improvement of symptoms and clinical signs was faster with the use of antimicrobial silk clothing than without, as occurred in our previous experience.

Moreover keeping on wearing silk clothing for another 4 months after stopping topical therapy no patient had relapse although every one continued the same chemo- or radiotherapy.



**Conclusions:** Until now antimicrobial silk clothing efficacy has been proved just for atopic dermatitis and other irritative and allergic skin diseases. This study shows that this fabric could be an useful adjuvant instrument even for the management of chemotherapy skin reactions. **In particular it could improve patients' compliance for oncologic therapy.**

- Fontanini C, Berti I, Monasta L, Longo G. DermaSilk in long-term control of infantile atopic dermatitis: a double blind randomized controlled trial. G Ital Dermatol Venereol. 2013 Jun;148(3):293-7.  
 - D'Antuono A, Baldi E, Bellavista S, Banzola N, Zauli S, Patrizi A. Use of DermaSilk briefs in recurrent vulvovaginal candidosis: safety and effectiveness. Mycoses. 2012 May;55(3):e85-9.  
 - Senti G, Steinmann LS, Fischer B, Kurmann R, Storni T, Johansen P, Schmid-Grendelmeier P, Wuthrich B, Kundig TM. Antimicrobial silk clothing in the treatment of atopic dermatitis proves comparable to topical corticosteroid treatment. Dermatology. 2006;213(3):228-33